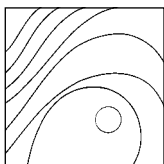


Immediate Loading of Zygomatic Implants Using the Intraoral Welding Technique: A 12-Month Case Series



Marco Degidi, MD, DDS*/Diego Nardi, DDS*
Adriano Piattelli, MD, DDS**/Chantal Malevez, MD, DDS***

The aim of this prospective study was to evaluate the concept of intraoral welding as a suitable technique for fabricating a fixed restoration for the edentulous maxilla the day of surgery using standard and zygomatic implants. Ten consecutive patients (four men, six women; mean age, 62.3 ± 11.6 years) were involved in this study, each of whom had an edentulous atrophic maxilla and received two standard and two zygomatic implants. All implants were loaded immediately with a fixed prosthesis supported by an intraorally welded titanium framework. Definitive abutments were connected to the implants, and a titanium bar was welded to them using an intraoral welding unit. This framework was used to support the definitive prosthesis, which was fitted the day of implant placement. Patients were checked for swelling, pain, and framework stability at 1, 3, 6, and 12 months. A total of 20 immediately loaded standard and 20 zygomatic implants were used. The cases included in this study achieved a 100% prosthetic success rate at the 12-month follow-up. No fracture or radiographically detectable alteration of the welded frameworks was noticed. It is possible to successfully rehabilitate the edentulous atrophic maxilla with a permanently fixed prosthesis supported by an intraorally welded titanium framework attached to standard and zygomatic implants the day of surgery. (Int J Periodontics Restorative Dent 2012;32:e154–e161.)

*Private Practice, Bologna, Italy.

**Professor, Dental School, University of Chieti-Pescara, Chieti, Italy.

***Professor, Department of Maxillofacial Surgery and Dentistry, Clinique St. Jean, Bruxelles, Belgium.

Correspondence to: Prof Adriano Piattelli, Via F. Sciucchi 63, 66100 Chieti, Italy;
fax: 011-39-0871-3554076; email: apiattelli@unich.it.

In 1988, Brånemark introduced the concept of the zygomatic implant—a titanium endosseal threaded implant available in different lengths with a built-in 45-degree angled platform designed to treat the severely resected or atrophic maxilla. The original clinical protocol prescribed the elevation of a full-thickness flap using a modified Le Fort I incision extended bilaterally around the base of the piriform rim with deglovement up to the inferior aspect of the infraorbital nerves and the inferior aspect of the body of the zygoma. A cross-arch rigid splint design was required using two trans-sinus zygomatic and at least two standard implants placed in the anterior maxilla. In 2003, Malevez et al¹ reported a 48-month 100% survival rate of 103 zygomatic implants placed in 55 edentulous patients using the “sinus window” Brånemark protocol. Using the same approach, Parel et al² reported a 100% survival rate for 27 restorations based on 25- to 60-mm-long zygomatic implants up to 12 years after surgery. In 2004, Brånemark et al³ reported a 5- to

10-year follow-up of 28 patients with severely resorbed edentulous maxillae, 13 of whom had previously undergone multiple-implant surgery in the jawbone that had failed. Three of 52 zygoma implants and 29 of 106 conventional implants failed, with an overall prosthetic rehabilitation survival rate of 96% after at least 5 years of function.

Stella and Warner⁴ proposed the "sinus slot" approach in 2000, which implemented use of a guide window made directly through the buttress wall of the maxilla to guide the insertion of the implant apex at the junction of the maxillary apophysis and the zygomatic buttress. This procedure eliminated the need for sinus elevation, thus simplifying the prosthetic protocol since the platform of the zygomatic implant emerges directly on the alveolar ridge. Ferrara and Stella⁵ reported a short-term success rate of 96% for 25 zygomatic implants placed in 16 patients using the sinus slot technique.

In 2006, Bedrossian et al⁶ evaluated a protocol for immediate function of two zygomatic and four standard implants supporting a fixed prosthesis in the completely edentulous maxilla. Fourteen patients rehabilitated with a maxillary complete denture had this denture converted to a fixed provisional prosthesis within 2 hours of surgery and were followed for at least 12 months. The authors reported that no failures occurred during the entire follow-up period.

The aim of this prospective study was to evaluate the concept

of intraoral welding⁷ as a suitable technique for fabricating a fixed prosthesis for the edentulous maxilla the day of surgery using conventional and zygomatic implants.

Method and materials

Any patient with a completely edentulous maxilla who was older than 18 years of age was considered eligible to be consecutively included in this prospective study. The condition of the opposing dentition was not considered to be a discriminatory factor. Patients were considered ineligible for this study if they met any of the following exclusion criteria: active infection in the sites intended for implant placement, systemic disease that could compromise osseointegration, radiation therapy treatment in the craniofacial region within the previous 12 months, smoking habits of more than 10 cigarettes per day, pregnancy or lactation, bruxism, suitable quantity of bone in the maxilla for a standard all-on-4/6 protocol, and partial maxillary edentulism.

This study was designed and conducted in full accordance with the World Medical Association Declaration of Helsinki, as revised in 2002. All patients signed an informed consent form. Each patient received two threaded, anodized-surface zygomatic implants (Brånemark System Zygoma, Nobel Biocare) and two 3.4- or 3.8-mm parallel screw, grit-blasted and acid-etched implants with an internal-hex connection (XiVE Plus, Dentsply)

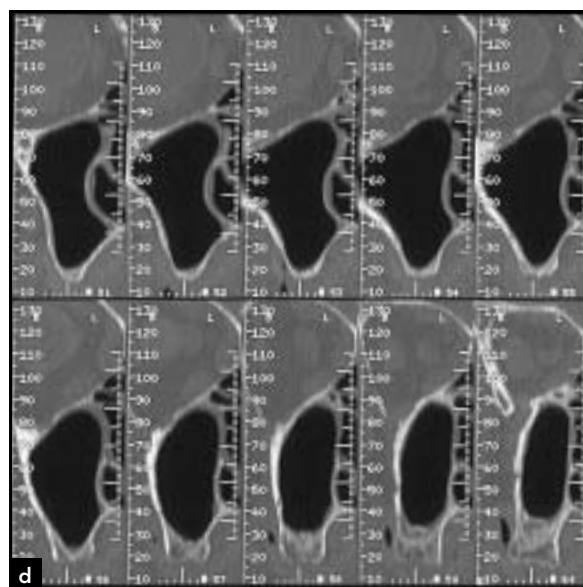
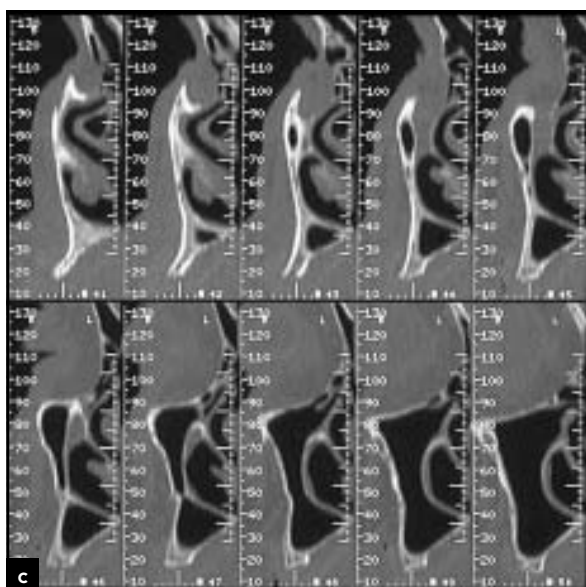
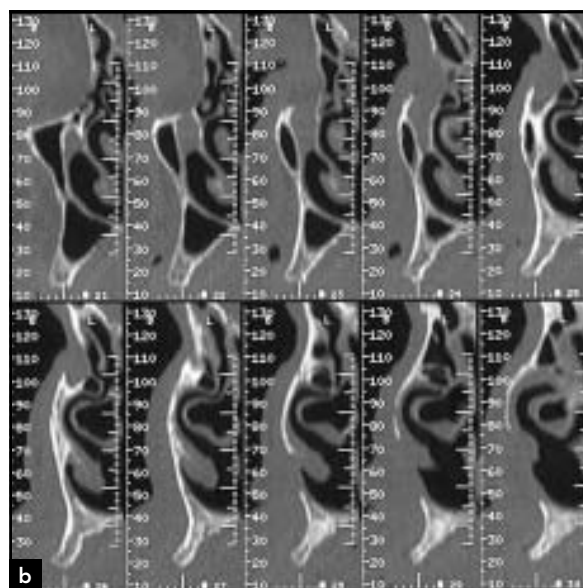
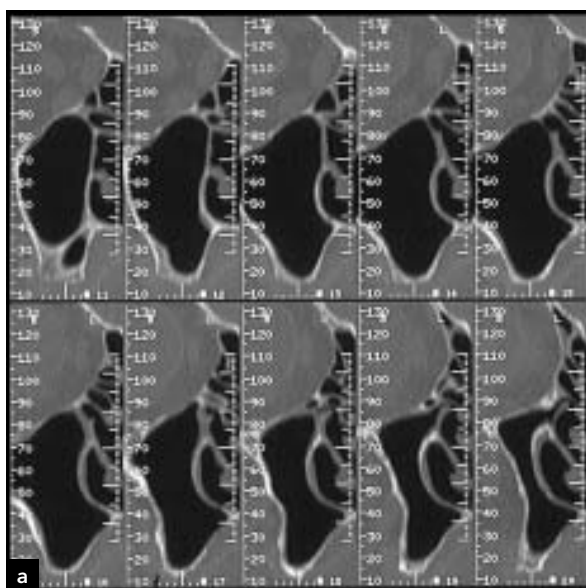
in the anterior maxilla. All implants were placed in healed sites by one experienced surgeon in a private dental practice in Bologna, Italy. During implant placement, the insertion torque was registered using a surgical unit (FRIOS Unit E, W & H Dentalwerk). Patients were dropped from the study if any implant lacked good primary stability or had an insertion torque < 25 Ncm.

Preoperative analysis of anatomical features and choice of implant length were made using computed tomography and periapical and panoramic radiography (Figs 1 and 2a to 2d). Impressions of the maxilla and mandible were taken, and laboratory casts were made. Highly wear-resistant commercial denture teeth (VITA PHYSIODENS, VITA Zahnfabrik) with an appropriate color shade and structure were chosen. According to the arch shape, 14 teeth were premounted on a maxillary cast on a semiadjustable articulator and joined with acrylic resin. This definitive acrylic resin cross-arch restoration was then hollowed out to create a space for housing the future titanium framework. All patients underwent the same antimicrobial prophylaxis using 500 mg beta-lactam antibiotic (amoxicillin, Pfizer) twice a day for 5 days, starting 1 hour before surgery. Intravenous sedation and local anesthesia (2% articaine/adrenaline 1:100,000) were administered at the time of surgery under the vigilance of an experienced anesthesiologist.

Surgery was initiated with a crestal incision that extended bilaterally to the zygomatic process

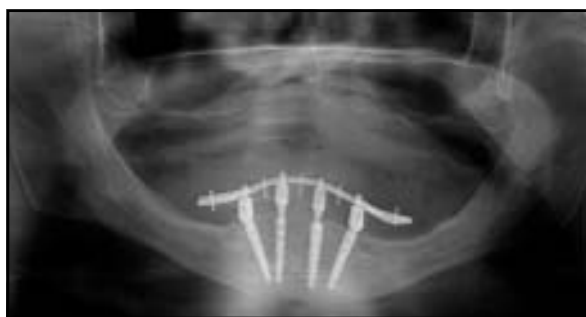

Fig 1 Preoperative panoramic radiograph.



Figs 2a to 2d Computed tomography scans taken postoperatively. (a) Right posterior maxilla; (b) right anterior maxilla; (c) left anterior maxilla; (d) left posterior maxilla.

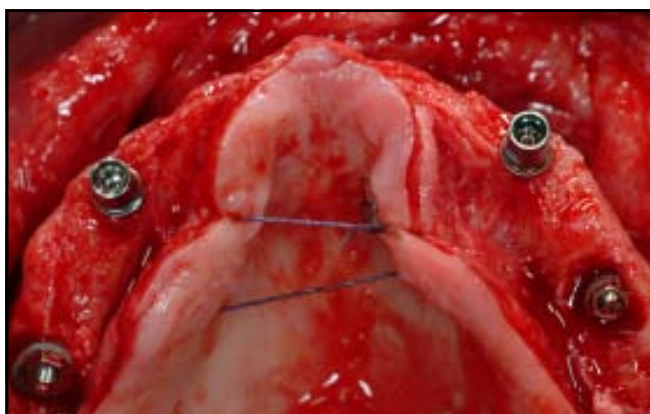


Fig 3 Clinical view of the implants immediately after surgery.

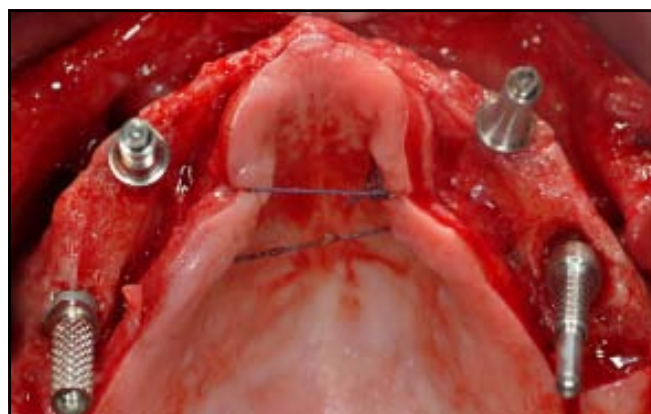


Fig 4 Welding abutments in place.

of the maxilla. A full-thickness flap was then carefully elevated around the base of the piriform rim up to the inferior emergence of the infra-orbital nerves and the top of the zygomatic body. In the presence of a knife-edge ridge, a mild osteoplasty was performed under profuse irrigation with sterile saline solution. The entrance site for the zygomatic implant was located in the area between the first and second premolars. Implants were placed running slightly posterior to the buttress and perforating the zygoma to the medial site, as suggested by Bothur et al.⁸ The final implant emergence was located between the first premolar and first molar areas at the center of the ridge crest. All standard implants (XiVE Plus) were placed with the 0.4-mm polished collar above the healed alveolar crest. Implants with lengths ranging from 11 to 15 mm were used in the anterior maxilla. No bone grafting material was employed. The internal-hex connection of the standard im-

plants was replaced by an abutment with an external circular and conical connection (MP, Dentsply Friadent) to compensate for the lack of parallelism between implants. These abutments were then connected to the implants by fastening screws with a 20-Ncm torque. A corrective abutment (Multi-unit Abutment, Nobel Biocare) was employed if the emergence angle of the zygomatic implant interfered with the prosthetic setup (Figs 3 and 4). A titanium cylinder (the so-called welding abutment) was then connected to each abutment with a long pin screw. Two-part abutments were used (abutment and retaining screw) to guarantee that the welded framework could be removed after welding. A 2.0-mm-diameter bar (Bio-Micron) made of commercially pure titanium (grade 2) was shaped with a pair of utility pliers (How Straight, Unitek 3M) so that its curve reached gentle contact with the abutment. The bar was then welded to the first distal

abutment on the left using an intraoral welding unit (Aptiva NS1100, EnneServizi). The process was repeated for all abutments.

Intraoral welding

The modern intraoral welding protocol is a refinement of the technique reported by Mondani and Mondani⁹ and Hruska.¹⁰ The welding process is subdivided into three stages: preparation, welding, and cooling.

Preparation

The two electrodes of the welding pincers were placed on either side of the bar and abutment, both of which must be clean and free of any surface oxidation. The copper electrodes at the extremity of the pincers were gently put in contact with the parts to be welded, and firm pressure was then applied. It is crucial to have complete contact between the curved bar and the

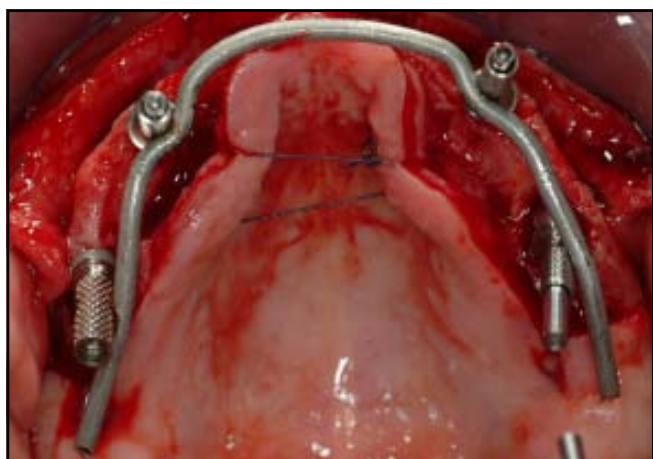


Fig 5 Welded framework.

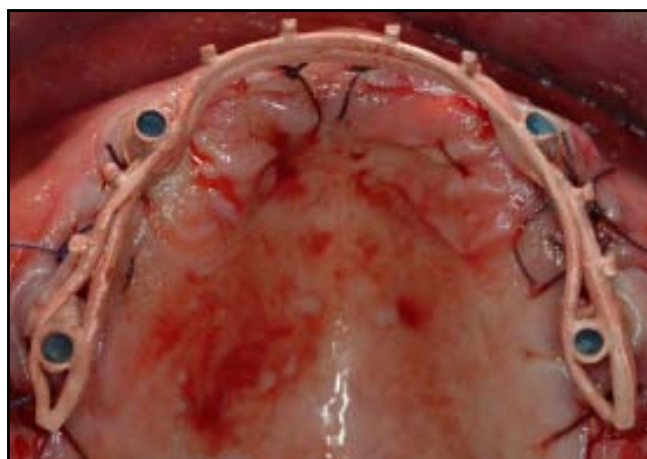

Fig 6 Opaqued framework.

welding abutment throughout the entire process. Firm and constant pressure must be applied to ensure a perfect joint between the parts to be welded. The presence of water or saliva does not compromise the quality of the welded joint. The surgical team and patient must wear protective eyewear during the entire process.

Welding

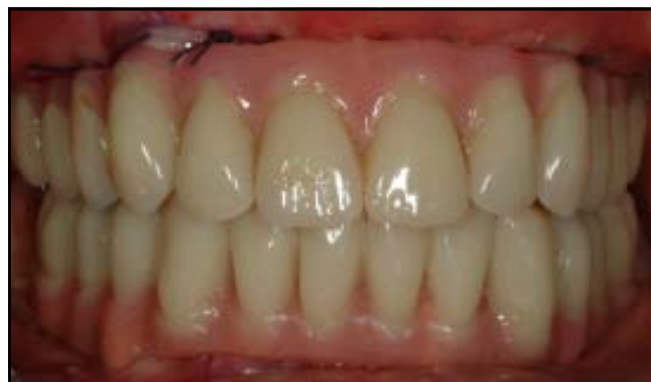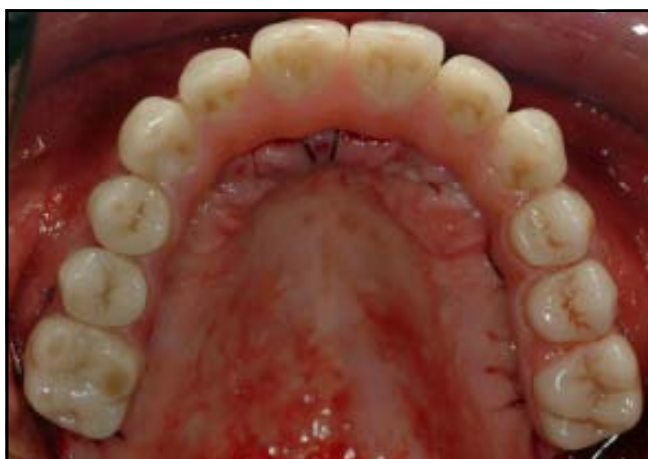An electric charge from a previously unloaded capacitor was transferred to the copper electrodes of the welding pincers. Electric current supplied to the electrodes instantly raises the temperature of the two titanium components to the fusion point. Welding was performed without the use of filler metal and took 2 to 5 milliseconds to carry out.

Cooling

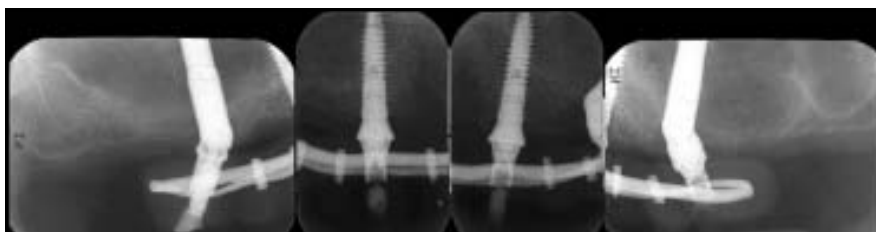
Thanks to the different thermal conductivities of the titanium parts (19 W/mK) and copper electrodes (386 W/mK), the process was carried out without producing any discomfort to the patient or damage to the surrounding tissue, since no perceptible heat was transmitted to the peri-implant area. The copper electrodes dissipate all heat that is generated. During this stage, the titanium crystallizes, and therefore the bar and abutment must be kept under firm pressure.

The framework created by welding the titanium bar to the implant abutments was removed, and the passivity of the entire structure was checked with the Sheffield 1 screw-test (Fig 5). Additional bars were welded extraorally using the

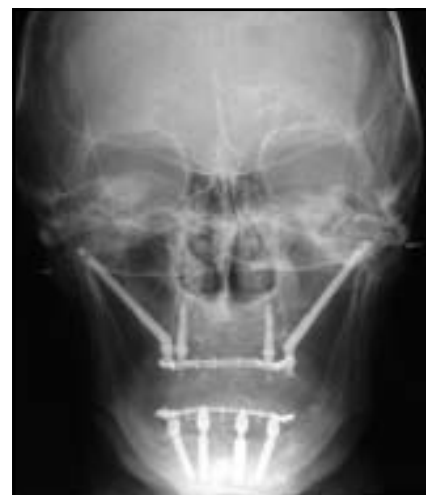same technique horizontally and vertically to increase the strength of the framework and improve the retention of the acrylic resin. The framework was then sandblasted (Modulars 3, Silfradent) and opaqued (OCS 2 Opaker, Dentsply Trubyte) to avoid metal light reflection through the acrylic resin. The soft tissue was positioned around the abutments and sutured into place (Fig 6). The opaqued framework was repositioned in the oral cavity, and the hollowed acrylic resin restoration was relined over the titanium framework using a small amount of cold-cured acrylic resin. The correct vertical length was checked and established using facial reference marks recorded prior to surgery. The restoration was then removed from the oral cavity and



Figs 7a and 7b Definitive restoration after surgery. (left) Occlusal view; (right) frontal view.



Figs 8a and 8b (above) Retroalveolar radiograph and (right) anteroposterior cranial radiograph taken with the restoration in place.



completely filled with heated pressure-processed acrylic resin. The restoration was trimmed, polished, and screw-retained the same day by fastening the screws with a torque of 20 Ncm. Screw holes were closed with light-cured composite resin (Figs 7a and 7b). A retroalveolar radiograph was taken to confirm the fit of the restoration (Figs 8a and 8b).

Follow-up

Biologic and technical complications and success and survival rates were all noted. Restoration success was defined as absence of fractures in both the acrylic resin superstructure and the welding joints, even if one or more implants supporting the restoration had to be removed.

Implant survival was defined as absence of radiologic translucency, implant mobility, swelling, or pain in the surgical site at the time of follow-up examinations.

Patients were recalled for follow-up immediately after surgery and fitting of the definitive restoration and 1, 3, and 6 months and 1 year after surgery.

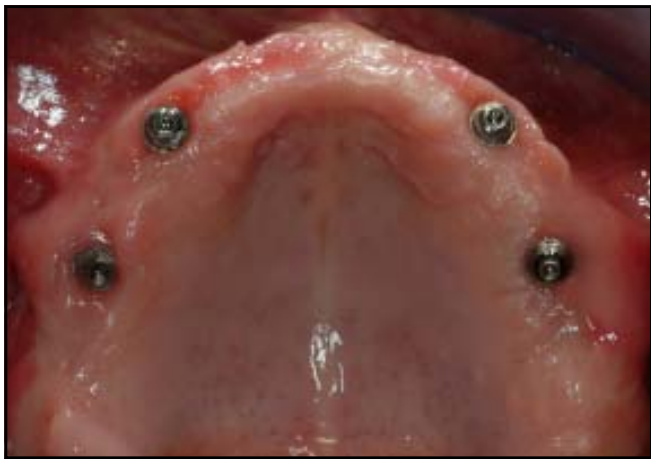

Fig 9 Clinical photograph of the implants after 6 months of healing.

Results

A total of 20 (50.0%) standard and 20 (50.0%) zygomatic implants were placed between July 2007 and November 2008. The mean age of the patients (four men, six women) was 62.3 ± 11.6 years at the time of surgery. Neither fractures nor complications occurred. At the 6-month follow-up, the prosthesis was removed and the clinical stability of each implant was checked (Fig 9). The cases included in this study achieved a 100% prosthetic success rate at the 12-month follow-up. Neither standard nor zygomatic implants incurred biologic complications.

Discussion

The feasibility of the immediate loading procedure over zygomatic implants has been demonstrated

by several authors, with success rates sometimes superior to those for standard implants placed in the same patient in the anterior maxilla. Davo et al¹¹ evaluated the survival rate of 36 immediately loaded zygomatic implants placed in 18 atrophied maxillae after a mean 14-month follow-up period. All patients had a fixed prosthesis screwed onto implants within 48 hours after implant placement. No zygomatic implant was lost, and 3 standard implants were lost over the observation period, resulting in survival rates of 100% and 95.6%, respectively.

Maló et al¹² studied the rehabilitation of maxillae with severe atrophy using extra-long implants placed externally to the maxilla and anchored only in zygomatic bone and reported a cumulative implant survival rate and prosthetic survival rate of 98.5% and 100%, respectively, after 1 year of immediate function.

To the best of the authors' knowledge, Aparicio et al¹³ recently reported the longest available follow-up regarding immediate/early loading of zygomatic implants for prosthetic rehabilitation of edentulous and severely resorbed maxillae. In that study, 47 zygomatic and 129 conventional implants were placed in patients who had less than 4 mm of available bone height and width distal to the canine pillars and who were followed for at least 2 and up to 5 years of function. The authors reported a cumulative survival rate of 100% for the zygomatic implants and a single failure of a conventional implant placed in the pterygoid plate after 52 months of loading (cumulative survival rate, 99.2%), concluding that immediate/early loading is a viable treatment modality for prosthetic rehabilitation of the severely resorbed maxilla using zygomatic and conventional implants.

With immediate cross-arch stabilization, there is no need for sinus elevation or grafting procedures and the time of treatment is decreased, which is the major advantage of the immediate loading procedure with zygomatic implants.^{11–13} Use of the intraoral welding technique further simplifies this procedure with a simple and repeatable prosthetic protocol. All components came from a standard prosthetic set and are compatible with implants manufactured by different companies. The prosthesis is delivered the same day as surgery, and the need for a customized individual open tray and difficult final impression procedures is eliminated, reducing costs and patient discomfort. The assembling and welding of the framework directly in the patients' mouths allows the creation of a precise and passive cross-arch structure, free from possible defects derived from standard impression procedures.

The soft tissue reaction at the extramaxillary placement of the zygomatic implant could be a cause of concern; however, favorable results were reported by Maló et al¹² and Aparicio et al¹³ using this technique. In this study, no biologic complications were recorded during the healing phase or 12 months after surgery.

Conclusion

Within its limitations, this study demonstrated the possibility of successfully rehabilitating the edentulous atrophic maxilla with a fixed permanent restoration supported by an intraorally welded titanium framework attached to conventional and zygomatic implants the day of surgery. More investigations over longer periods of time are required to better determine the long-term success of this approach.

Acknowledgment

The authors would like to thank Mr Gianluca Sighinolfi, dental technician, for his invaluable technical support.

References

1. Malevez C, Daelemans P, Adriaenssens P, Durdu F. Use of zygomatic implants to deal with resorbed posterior maxillae. *Periodontol* 2000 2003;33:82–89.
2. Parel SM, Brånemark PI, Ohnrell LO, Svensson B. Remote implant anchorage for the rehabilitation of maxillary defects. *J Prosthet Dent* 2001;86:377–381.
3. Brånemark PI, Gröndahl K, Ohnrell LO, et al. Zygoma fixture in the management of advanced atrophy of the maxilla: Technique and long-term results. *Scand J Plast Reconstr Surg Hand Surg* 2004;38:70–85.
4. Stella JP, Warner MR. Sinus slot technique for simplification and improved orientation of zygomatic dental implants: A technical note. *Int J Oral Maxillofac Implants* 2000;15:889–893.
5. Ferrara ED, Stella JP. Restoration of the edentulous maxilla: The case for the zygomatic implants. *J Oral Maxillofac Surg* 2004;62:1418–1422.
6. Bedrossian E, Rangert B, Stumpel L, Indresano T. Immediate function with the zygomatic implant: A graftless solution for the patient with mild to advanced atrophy of the maxilla. *Int J Oral Maxillofac Implants* 2006;21:937–942.
7. Degidi M, Nardi D, Piattelli A. Immediate loading of the edentulous maxilla with a final restoration supported by an intraoral welded titanium bar: A case series of 20 consecutive cases. *J Periodontol* 2008;79:2207–2213.
8. Bothur S, Jonsson G, Sandahl L. Modified technique using multiple zygomatic implants in reconstruction of the atrophic maxilla: A technical note. *Int J Oral Maxillofac Implants* 2003;18:902–904.
9. Mondani PL, Mondani PM. The Pierluigi Mondani intraoral electric solder. Principles of development and explanation of the solder using syncrystallization [in Italian]. *Riv Odontostomatol Implantoprotesi* 1982;4:28–32.
10. Hruska AR. Intraoral welding of pure titanium. *Quintessence Int* 1987;18:683–688.
11. Davo R, Malevez C, Rojas J. Immediate function in the atrophic maxilla using zygoma implants: A preliminary study. *J Prosthet Dent* 2007;97(suppl):S44–S51 [erratum 2008;99:167].
12. Maló P, Nobre Mde A, Lopes I. A new approach to rehabilitate the severely atrophic maxilla using extramaxillary anchored implants in immediate function: A pilot study. *J Prosthet Dent* 2008;100:354–366.
13. Aparicio C, Ouazzani W, Aparicio A, et al. Immediate/early loading of zygomatic implants: Clinical experiences after 2 to 5 years of follow-up. *Clin Implant Dent Relat Res* 2010;12(suppl 1):e77–e82.